

# Anal Cancer: A Multispecialty Disease, a Multispecialty Cure

## Part IV—Anal Canal Cancer: Unusual Forms of the Disease

BY GARY H. HOFFMAN, MD

### Adenocarcinoma

Squamous cell cancer of the anal canal is rare and adenocarcinoma is rarer still, accounting for 10% of all anal cancers.<sup>1,2</sup> The 3 types of anal adenocarcinoma are those arising in the anorectum, in the anal glands, and in an anorectal fistula.<sup>3</sup>

Occurring most proximally is the adenocarcinoma arising from the rectal type of anal mucosa. It appears similar to a rectal adenocarcinoma. The second type of adenocarcinoma arises from the base of the anal glands and may be an adenomatous type of cancer or a squamous variety depending on its cellular origin. The third type arises from a chronic anorectal fistula and may be a well-differentiated mucinous adenocarcinoma.

It is useful to understand the anatomy and histology of the anal canal in order to appreciate the derivation of these tumors.

The anal canal is a small but complicated structure (Figure 1). It is 4 cm in length and begins at the anorectal ring, which is formed by the upper edge of the internal anal sphincter and the puborectalis muscle. The canal extends to the anal verge. Distal to this is the perianal skin. The perianal skin extends outward, onto the buttocks for 5 cm.

The histology of the anal canal is intricate and variable. The lining of the proximal canal is mucosal or endodermal, and is composed of a columnar epithelium. The columnar epithelium gradually transitions into a cutaneous or ectodermal

squamous epithelium<sup>4</sup> through the anal transition zone (ATZ). The ATZ is 1 cm in length and ends at the dentate line, which is located approximately 2 cm proximal to the anal verge. The dentate line is the remnant of the embryonic proctodeal membrane, or junction of the endoderm and ectoderm. Distal to the dentate line, the anal epithelium approximates that of skin except that it is non-keratinized and does not contain hair or glandular structures. This area is referred to as the anoderm. At the anal verge, the lining becomes that of true keratinized skin with hair, sebaceous glands, and sweat glands.

The lining of the anal canal proximal to the dentate line is thrown into pleats or columns due to the narrowing size of the canal as it moves distally. The columns, 5 to 15 in number, are termed the columns of Morgagni. At the lower end of each column, and between each column is a small pocket, or anal crypt. These crypts connect to anal glands.

Anal glands begin at the crypt and extend outward. The ducts of the anal glands are lined by a squamous epithelium. This epithelium transitions into a columnar epithelium deep in the gland. Interspersed along the length of this epithelium are mucus-secreting cells, or goblet cells. The glands are involved with the pathogenesis of anorectal abscesses, fistulous disease, and with rarely occurring anal fistula malignancies.

The rectal type of adenocarcinoma looks like a distal colon adenocarcinoma and usually is indistinguishable from a colorectal neoplasm. This is the most common type of anal canal adenocarcinoma.

The adenocarcinoma arising in a fistula

is a well-differentiated cancer most commonly arising in patients with a chronic anal fistula or perianal disease.

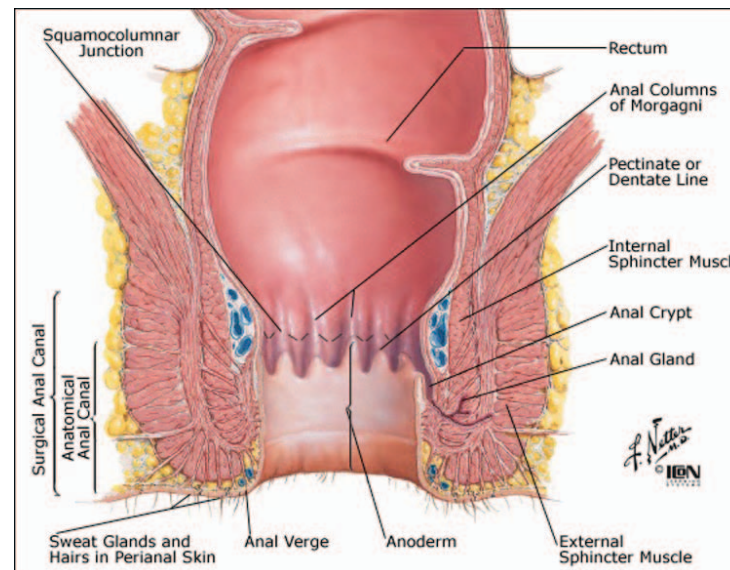
Anal glandular adenocarcinomas commonly arise in the sixth to eighth decades of life.<sup>2,5</sup> These tumors may present with signs and symptoms identical to other benign anorectal disorders. In a study of 21 patients by Jensen,<sup>6</sup> patients complained of pain, leakage, bleeding, pruritus, prolapse, or weight loss. Exams disclosed induration, an associated abscess or fistula, or a mass. An initial misdiagnosis was common. Patients experienced complaints and symptoms for 18 months before the correct diagnosis was made. Tumors of the anal canal averaged 5 cm in length and those of the perianal area averaged 10 cm in length. Sixty-two patients presented with regional or distant metastases and 20 of 21 patients were dead

within 18 months after treatment. These lesions often arise in an extramucosal location and there is no involvement of the mucosa. In the same series reported by Jensen, 9 tumors were found in the ischioanal space, 7 were found in the anal canal, and 5 were seen in a fistula.<sup>6</sup> With the variable nature of the glandular mucosa, the pathology of glandular cancer may be an adenocarcinoma or squamous cancer.<sup>7</sup> Because there are so few reported cases of anal adenocarcinoma, uniform treatment recommendations based on solid data are difficult to obtain. It is clear that treatment results are relatively poor and this disease seems to be much more aggressive than its anal squamous cell counterpart<sup>8</sup> when matched for local recurrence rates and survival rates.

Treatment regimens have included wide local excision (WLE), abdominoperineal resection (APR), radiation, chemoradiation, and combined modality therapy, usually pre- or postoperative chemoradiation and an APR.

WLE may be possible in small tumors of the proximal anal canal. The tumors must be mobile, well differentiated, and should not invade the sphincters. These types of tumors are rare.

In a large multicenter study by Belkacemi,<sup>5</sup> 82 patients with anal canal adenocarcinoma were evaluated for treatment results. The 3 treatment groups consisted of radiotherapy with surgical extirpation, chemoradiation, or an APR. The 5-year survival and disease-free survival (DFS) rates were best in the chemoradiation group. Five and 10-year overall survival rates were 58% and 39%, respectively. Disease-free rates at 5 and 10 years were 54% and 20%, respectively. Additionally, the authors concluded that an APR should be reserved for salvage. The independent predictors of survival were T stage, N stage, histologic grade, and

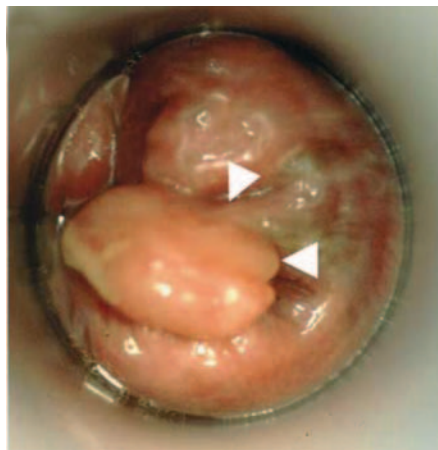


**FIGURE 1. ANATOMY OF THE ANAL CANAL.**

June 2011. Used with permission of Elsevier. All rights reserved.

[www.PreventCBDinjury.com](http://www.PreventCBDinjury.com)





**FIGURE 2. POLYPOID ANAL MELANOMA (BOTTOM ARROW) WITH PIGMENT AT BASE OF POLYPOID TUMOR (TOP ARROW).**

From: Weyandt GH, Eggert AO, Houf M, et al. *Br J Cancer*. 2003;89:2019-2022. Reprinted with permission.

mode of treatment.

Two other studies suggested that survival rates of 60% could be obtained with chemoradiation and surgery.<sup>2,9</sup> In the study by Beal et al,<sup>2</sup> the average radiation dose was 50.4 Gy. The chemotherapy was based on the cell type and was most commonly 5-fluorouracil with leucovorin for treatment of adenocarcinoma. The authors stressed that their study, as well as other studies, contained too few patients to confidently make definitive treatment recommendations. They suggested that APR with pre- or postoperative chemoradiation “achieves reasonable local control and survival.”

Chemoradiation with surgery as the primary mode of treatment seems to be the most common approach for adenocarcinoma of the anal canal.

## Melanoma

Anal melanoma is an ominous tumor. Fortunately, it also is a rare tumor. Fewer than 500 cases have been reported, and it constitutes between 0.5% and 5% of all anal malignancies.<sup>10</sup> Melanoma of the anal canal is the third most common site of occurrence after skin and ocular melanoma.<sup>11</sup> Patients with anal melanoma often are white females with an average age of 63 years. The disease rarely is reported in the black or Asian populations.<sup>12-14</sup> Women are twice as likely as men to have this lesion. Although the etiology is unknown, one report of 117 cases detailed a tripling of the incidence of the disease in males younger than 44 years of age in San Francisco when compared with other geographic locations (14.4 vs. 4.8 per 10 million population). In this study, the male-to-female ratio was 1:1.72 with an average age at diagnosis of 57 years for men and 71 years for women. Men had a survival advantage over women at 1 and 2 years (62.8% vs 51.4% at 1 year, and 40.6% vs 27.7% at 2 years, respectively). This new bimodal trend was noted and HIV was suggested as a risk factor.<sup>15</sup>

The lesion may arise at any location in

the anal canal.<sup>13,16</sup> Bleeding is the usual patient complaint, followed by pain. Altered bowel habits and tenesmus also are reported. Weight loss is common. The most common presenting sign is an anal mass. Seventy-five percent of patients have a mass greater than 1 cm, and the average diameter is 4 cm.<sup>17</sup> Many patients have associated involved inguinal lymph nodes.

Anal melanoma often is confused with a thrombosed hemorrhoid. Larger lesions may be polypoid and ulcerated, distinguishing the lesion from a thrombotic hemorrhoid (Figure 2). In one

study, 71% of patients had “gross and/or histologic pigmentation,”<sup>18</sup> whereas other studies have found these lesions to be amelanotic in 41% of cases.<sup>16,19</sup> If melanin is seen on microscopic examination, the diagnosis is straightforward. In the amelanotic form, the presence of “malignant cells in clusters” helps to differentiate this lesion from an undifferentiated squamous cell carcinoma.<sup>19</sup>

Thirty-eight percent of patients had either metastatic nodal involvement (perirectal, perianal, and mesenteric nodes, followed by inguinal node disease) or distant metastases to the liver

and lung. Between 38% and 62% of patients presented initially with metastatic disease to lymph nodes, and not uncommonly to distant sites as well. Submucosal spread is common.<sup>20</sup>

Although there are conflicting issues in trying to choose a treatment modality and predict survival rates using various parameters, one point is clear: 5-year survival rates are dismal. Survival rates range between 0% and 29%.<sup>10,18, 21-23</sup> As many as 35% of patients have metastatic disease at the time of presentation, and one study showed that in patients whose

see ANAL CANCER page 12

**The evils of adhesive failure are lurking around every dressing and device**

**Mastisol® protects your patients against the risks and costs of device dislodgement and tape failure**

**Mastisol—committed to the mission of healthcaring**

- Powerful adjunctive adhesive proven to maintain integrity of devices, tapes and dressings minimizing dislodgements and risk of infection
- Lower incidences of post-operative contact dermatitis and skin discoloration than 'tincture of benzoin'
- Truplied for more than 2 million adjunctive adhesive applications every year<sup>2</sup>

**Make sure. Be secure.**

**mastisol**  
LIQUID ADHESIVE

*Where good outcomes begin*

For product related questions, please contact your sales consultant or Eloquent Healthcare®, Inc. Toll Free: 1.877.433.7626, or on the Web at [www.mastisol.com](http://www.mastisol.com). Mastisol is an essential product in the Eloquent Healthcare®, Inc. portfolio.

1. Luster CB. The polypoid mass of wound adhesives. *Care mastisol* (wound adhesive), USP. JSSM. 1992;18:900. 2. Mastisol design unit sales, 2006, 2007, 2008 and 2009. Data on file. Eloquent Healthcare®, Inc. Farmdale, MI. Mastisol® is a registered trademark of Eloquent® Inc. AONM 05/10

2010 Eloquent Healthcare®, Inc.



## ANAL CANCER

▼ Continued from page 11

tumors are thicker than 10 mm, cure is not possible.<sup>22</sup>

In a review of the Mayo Clinic experience, no single factor predicted survival. Factors evaluated were gender, size of the lesion, presence of melanin, depth of penetration, positive perirectal lymph nodes and WLE versus APR.<sup>21</sup> Interestingly, the Memorial Sloan-Kettering (MSK) series found that the only long-term survivors were women.<sup>18</sup>

Available surgical options include wide local excision or abdominoperineal resection. In MSK and Mayo Clinic series, overall 5-year survival rates were 17% and 22%, respectively, and were unrelated to the type of surgical procedure used to extirpate the disease.<sup>18,21</sup> However, the MSK series of 85 patients suggested that 5-year, DFS using an "APR was more favorable than that of patients who underwent local procedures only, although this was not statistically significant (27% vs 5%, APR vs local procedures, respectively;  $P=0.11$ )."<sup>18</sup> This report concluded that an APR should be used in those patients with localized anorectal melanomas and no evidence of nodal disease. However, the Mayo Clinic series of 50 patients found 5-year survival and recurrence rates to be the same after curative WLE or APR,<sup>21</sup> but concluded that "wide local excision with a negative margin of at least 1 cm is suggested as the treatment of choice. APR should be reserved for tumor not amenable to local excision or for palliative treatment of large obstructive lesion [sic] until effective adjuvant therapies are available."

One study examined tumor thickness, comparing anorectal melanoma to cutaneous melanoma in an attempt to formulate guidelines for treatment. The study recommended WLE with a 1 cm margin of normal tissue for tumors less than 1 mm in thickness, and WLE with a 2 cm margin of normal tissue in tumors between 1 and 4 mm in thickness, as long as the internal sphincter was tumor-free; an APR was recommended for all other tumors.

Most authors note that with documented regional metastatic disease or distant metastases, patients should be spared an APR and permanent colostomy, as long-term survival rates are almost nonexistent. However, in those patients with bulky tumors, or in patients in whom the surgeon is unable to obtain 1- to 2-cm tumor-free margins with a WLE, or in patients with tumor involvement of the anal sphincter, or in those patients who would be rendered incontinent after a WLE, an APR may be the treatment of choice.<sup>4</sup>

Numerous immunologic and adjuvant

chemotherapeutic treatments have been tried with little benefit in patients with anal melanoma.<sup>23</sup> Radiation therapy is of unproven benefit as well. Local control, although possible with surgical treatment, often is useless, as distant metastatic disease is a major cause of death.<sup>23,24</sup>

### Neuroendocrine Carcinomas

Also called a small cell carcinoma, a large cell neuroendocrine tumor, or a Merkel cell carcinoma, this tumor is so named because it is derived from cells of both the endocrine system and the nervous system. Neuroendocrine cells are found in many organ systems and tissues, with the gastrointestinal tract harboring the largest volume of these cells. These tumors are rare, comprising less than 1% of all lower digestive tract cancers. Most neuroendocrine tumors are found in the rectum and cecum.<sup>25,26</sup> In a study from the MSK Cancer Center of 6,495 patients with colorectal cancer over a 23-year period, 6 neuroendocrine tumors, representing less than 0.1% of all colorectal malignancies, were found in the anal canal.<sup>27</sup>

Colorectal neuroendocrine tumors are classified as either low-grade carcinoids or high-grade neuroendocrine carcinomas. The neuroendocrine lesions can be further subdivided into small cell carcinomas or large cell neuroendocrine carcinomas. All of these high-grade neuroendocrine tumors have at least 50% of the tumor demonstrating typical neuroendocrine characteristics. "These features include a densely cellular, solid growth pattern, with cells arranged in nests having minimal intercellular stroma." There is no gland formation. There are features of necrosis and a mitotic rate "of greater than 10 per high-power" field on microscopy.<sup>27</sup> Based on cytological features, further subdivision into small cell carcinoma or large cell neuroendocrine carcinoma is possible, with the small cell form resembling the pulmonary form of small cell cancer. This division into small and large cell forms resembles the classification of pulmonary neuroendocrine tumors.<sup>28</sup> The small cell carcinoma does not require immunohistochemical documentation and may be diagnosed solely by hematoxylin and eosin microscopy. The large cell variant does require immunohistochemical documentation, with the finding of at least 1 of 3 neuroendocrine markers (chromogranin, synaptophysin, and neuron-specific enolase) in at least 10% of the tumor cells.<sup>27</sup>

In the MSK study, 80% of all neuroendocrine tumors stained positive immunohistochemically for neuroendocrine markers and most presented at an advanced stage, although no mention was made as to the specific stage of presentation seen in anal lesions.<sup>27</sup>

Diagnosis involves a high index of

suspicion in patients with any type of anorectal complaint. An obvious lesion removed surgically will then be submitted for the appropriate microscopic and immunohistochemical evaluation.

As these tumors are rare, no single series can reliably evaluate the different modes of available treatment and survival statistics. Patients have been treated with excision, radical extirpative procedures with or without adjuvant therapy, radiation alone, or chemotherapy alone. Staging is important, as up to 85% of extrapulmonary small cell tumors in one series presented with metastatic disease not amenable to surgical cure.<sup>27</sup> Small cell variants with documented metastatic spread can be treated like pulmonary tumors, with cisplatin and etoposide. Other chemotherapeutic regimens including cyclophosphamide, doxorubicin, and vincristine have been used in treatment programs. The success of chemotherapeutic treatment of anal lesions has not been verified.

Although not validated, it would make sense to treat patients with disease limited to the anal canal with extirpative surgery and/or chemoradiation, akin to the treatment for anal adenocarcinoma.

In the study by Bernick et al., looking at all treatment modalities in 36 patients who completed treatment and follow-up, median survival was 10.5 months, with an overall disease-specific median survival of 16 months.<sup>27</sup> Small cell carcinomas and large cell neuroendocrine carcinomas demonstrated similar survival curves. One-year, 2-year and 3-year survival rates were 46%, 26%, and 13%, respectively.

These are aggressive tumors and are difficult to treat. The best that can be said of them is that they are rare.

### References

- Basik M, Rodriguez-Biga MA, Penetrante R, Petrelli NJ. Prognosis and recurrence patterns of anal adenocarcinoma. *Am J Surg*. 1995;169(2): 233-237.
- Beal KP, Wong D, Guillem JG, et al. Primary adenocarcinoma of the anus treated with combined modality therapy. *Dis Colon Rectum*. 2003;46(10):1320-1324.
- Fenger C, Frisch M, Marti MC, Parc R. Tumors of the anal canal. Hamilton, S. R., Aaltonen, L. A., eds. In: *WHO Classification of Tumors. Pathology and Genetics of Tumors of the Digestive System*. Lyon, France: IARC Press; 2002:146-155.
- Wolff BG, Fleshman JW, Beck DF, Pemberton JH, Wexner SD. *The ASCRS Textbook of Colon and Rectal Surgery*. New York, NY: Springer Science+Business Media, LLC; 2007:494.
- Belkacemi Y, Berger C, Poortmans P, et al. Management of primary anal canal adenocarcinoma: a large retrospective study from the Rare Cancer Network. *Int J Radiat Oncol Biol Phys*. 2003;56(5):1274-1283.
- Jensen SL, Shokouh-Amiri MH, Hagen K, et al. Adenocarcinoma of the anal ducts: a series of 21 cases. *Dis Colon Rectum*. 1988;31(4): 261-272.
- Hobbs CM, Lowry MA, Owen D, Sobin LH. Anal gland carcinoma. *Cancer*. 2001;92(8): 2045-2049.
- Papagikos M, Crane C, Skibber J, et al. Chemoradiation for adenocarcinoma of the anus. *Int J Radiat Oncol Biol Phys*. 2003;55(3):669-678.
- Klas JV, Rothenberger DA, Wong WD, Madoff RD. Malignant tumors of the anal canal: the spectrum of disease, treatment and outcomes. *Cancer*. 1999;85(8):1686-1693.
- Malik A, Hull TL, Floruta C. What is the best surgical treatment for anorectal melanoma? *Int J Colorectal Dis*. 2004;19(2):121-123.
- Mason JK, Helwig EB. Anorectal melanoma. *Cancer*. 1966;19(1):39-50.
- Gervasoni JE Jr, Wanebo HJ. Cancers of the anal canal and anal margin. *Cancer Invest*. 2003;21(3):452-464.
- Billingsley KG, Stern LE, Lowy AM, et al. Uncommon anal neoplasms. *Surg Oncol Clin N Am*. 2004;13(2):375-388.
- Chang AE, Karnell LH, Menck HR. The National Cancer Data Base report on cutaneous and noncutaneous melanoma: a summary of 84,836 cases from the past decade. *Cancer*. 1998;83(8):1664-1678.
- Cagir B, Whiteford MH, Topham A, et al. Changing epidemiology of anorectal melanoma. *Dis Colon Rectum*. 1999;42(9):1203-1208.
- Ward MW, Romano G, Nicholls RJ. The surgical treatment of anorectal malignant melanoma. *Br J Surg*. 1986;73(1):68-69.
- Quan SH. Malignant melanoma of the anorectum. *Seminars in Colon and Rectal Surgery*. 1995;6 (1995):166-168.
- Brady MS, Kavolius MD, Quan SH. Anorectal melanoma: a 64-year experience at Memorial Sloan-Kettering Cancer Center. *Dis Colon Rectum*. 1995;38(2):146-151.
- Chiu YS, Unni KK, Beart RW Jr. Malignant melanoma of the anorectum. *Dis Colon Rectum*. 1980;23(2):122-124.
- Cooper PH, Mills SE, Allen MS Jr. Malignant Melanoma of the Anus. Report of 12 patients and analysis of 255 additional patients. *Dis Colon Rectum*. 1982;25(7):693-703.
- Thibault C, Sagar P, Nivatvongs S, et al. Anorectal melanoma: an incurable disease? *Dis Colon Rectum*. 1997;40(6):661-668.
- Weyandt GH, Eggert AO, Houf M, et al. Anorectal melanoma: surgical guidelines according to tumour thickness. *Br J Cancer*. 2003;89:2019-2022.
- Bullard KM, Tuttle TM, Rothenberger DA. Surgical therapy for anorectal melanoma. *J Am Coll Surg*. 2003;196(2):206-211.
- Roumen R. Anorectal melanoma in The Netherlands: a report of 63 patients. *Eur J Surg Oncol*. 1996;22(6):598-601.
- Saclarides TJ, Szeluga D, Staren ED. Neuroendocrine cancers of the colon and rectum: results of a ten-year experience. *Dis Colon Rectum*. 1994;37(7):635-642.
- Hung SS. Small cell carcinoma of the colon: a case report and literature review. *J Clin Gastroenterol*. 1989;11(3):335-339.
- Bernick PE, Klimstra DS, Shia J, et al. Neuroendocrine carcinomas of the colon and rectum. *Dis Colon Rectum*. 2004;47:163-169.
- Travis WD, Gal AA, Colby TV. Reproducibility of neuroendocrine lung tumor classification. *Human Pathology*. 1998;29:272-279.



—Dr. Hoffman is attending surgeon and instructor in the Division of Colorectal Surgery at Cedars-Sinai Medical Center, and attending surgeon in the Division of General Surgery and associate clinical professor of surgery at the David Geffen School of Medicine, University of California, Los Angeles. He is a senior member of Los Angeles Colon and Rectal Surgical Associates ([www.lacolon.com](http://www.lacolon.com)).